



Indonesian Journal of Rheumatology

Journal Homepage: <https://journalrheumatology.or.id/index.php/IJR>

Single Case Experience of Immunosuppressant Administration to Systemic Sclerosis-ILD Patients with Aspergilloma

Wilujeng Anggraini^{1*}, Perdana Aditya Rahman²

¹Resident of Internal Medicine, Saiful Anwar General Hospital, Malang, Indonesia

²Supervisor at Rheumatology Division, Internal Medicine Department, Saiful Anwar General Hospital, Malang, Indonesia

ARTICLE INFO

Keywords:

Systemic sclerosis
Interstitial lung disease
Aspergilloma

*Corresponding author:

Wilujeng Anggraini

E-mail address:

ajeng0989@student.ub.ac.id

All authors have reviewed and approved the final version of the manuscript.

<https://doi.org/10.37275/IJR.v14i1.197>

ABSTRACT

Background: Systemic sclerosis (SSc) is a chronic autoimmune disease that still poses a great challenge to clinicians. SSc is characterized by immune dysregulation and progressive fibrosis that typically affects variable internal organ involvement such as lungs. Interstitial lung disease (ILD) is a common manifestation of SSc and a leading cause of death. The immunosuppressive drug is the main treatment to suppress the inflammation process in SSc. **Case presentation:** In this case we report a 40-year-old female to suffer ILD-SSc. According to High-Resolution Computed Tomography (HRCT) thorax, we found that it was interstitial lung disease with aspergilloma. She got methylprednisolone 3x8 mg and azathioprine 2x50 mg. At the end of the treatment, the patient showed improvement in her clinical condition and showed no worsening condition in the HRCT evaluation for her fungal aspergilloma. **Conclusion:** Systemic sclerosis (SSc) is a rare autoimmune disease involving the skin and internal organs. The immunosuppressive agent is still the drug of choice for most autoimmune diseases. Immunosuppressive may promote fungal growth and have been associated with increased risk in most serious fungal diseases including aspergilloma.

1. Introduction

Systemic sclerosis (SSc) is an autoimmune disease that is characterized by the distinctive pathogenic triad of dysregulation of innate and adaptive immunity, microvascular damage, and generalized fibrosis in multiple organs. Although skin fibrosis is the distinguishing hallmark, the changes might involve the lungs, gastrointestinal tract, kidneys, and heart to determine the clinical outcome. Interstitial lung disease (ILD) is the predominant lung manifestation in this setting.^{1,2}

Human lungs are constantly exposed to airborne fungi, which is a relatively ubiquitous component of our external environmental microbiome. Of all fungi,

Aspergillus fumigatus and *Aspergillus niger* are common colonizers. The primary port of entry for aspergillus spores is through the respiratory tract, although they can be commensals within the external auditory canal as well. In a diseased lung or with systemic immunodeficiency, these filamentous organisms then proliferate rapidly and become consequential. Nearly 60% of aspergilloma thrives in a poorly drained and avascular cavitary space. *Aspergillus*, once harbored within cavitary airspace, adheres to the wall with its conidia, then germinates and, in the process, evokes inflammatory debris, forms an amorphous mass identified as an aspergilloma. In the very early stages, an ulceration or irregular

cobblestoned cavity wall or floor maybe the only pathological findings. Even with advanced disease, aspergilloma is most often mobile within the cavity, and thus changes position with respect to the cavity in radiological images taken in different postures of the subject.³⁻⁶ Recurrent pulmonary infections are common and infectious complication is the most common cause of death in such patients. But a co-existence of ILD with aspergilloma is extremely rare and scarcely found in the literature.^{1,2}

2. Case Presentation

A 40-year-old female with systemic sclerosis visited Rheumatology Outpatient Clinic complaining of shortness of breath accompanied by cough,

intermittently since February 2020. CXR shows reticulogranular infiltrates with multiple thin-wall cavity air-fluid levels inside both lungs. HRCT thorax shows subpleural honeycombing appearance dominantly on the basal side with traction bronchiectasis thsubstantiatesate interstitial lung disease UIP pattern with fungus ball aspergilloma and bilateral pleural nodular thickening.

Physical examination showed good awareness, blood pressure was 110/70 mmHg, pulse rate was 95 bpm, respiratory rate was 20 tpm, axillary temperature 36.2°, and C, and oxygen saturation was 99% room air. Pictures below show the clinical features of the patient and Rodnan skin score.

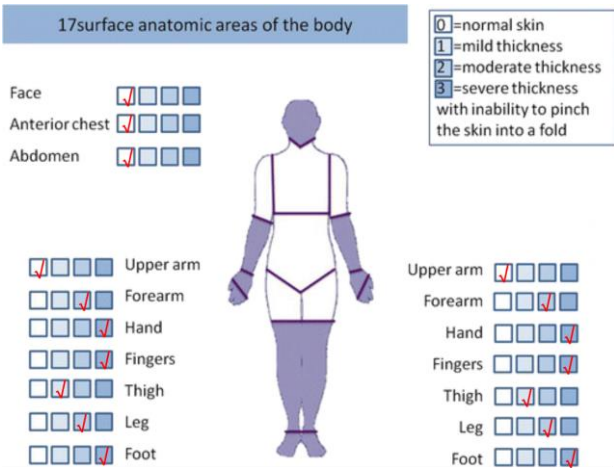


Figure 1. Rodnan skin score

Figure 1 shows the Rodnan skin score of the patient. From the patient’s face, anterior chest, and abdomen the Rodnan skin score was 0 which is interpreted as normal skin. As well as the upper arm. However, from the forearm, hand, fingers, thigh, leg, and foot on both sides the score was 2-3 which is interpreted as moderate until severe thickness.

There were also erythematous papules and patches, hyperpigmentation, multiple, unclear edge with round shapes, irregular excoriation at several

locations, and thin white squama that spreads over the body, especially in the armpits, buttocks, and groin. We also found crackle sounds at basal lung bilateral. Laboratory results showed increased leukocyte (20090/μl) and neutrophil (89,5%), also decreased CD4 (345/μl) which also leads to the diagnosis of fungal ball aspergilloma. HRCT Thorax images of the patient are shown in Figure 2.

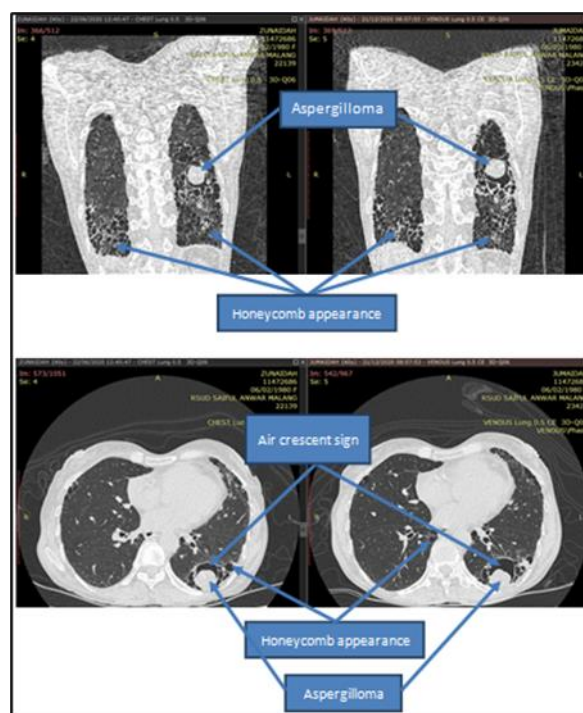


Figure 2. The patient's HRCT thorax showed aspergilloma, honeycomb appearance, and air crescent sign. I= baseline; II= 6 months after follow-up.

We decided to start an immunosuppressive agent to delay the progressivity of SSc-ILD. MMF 1 gram bid and methylprednisolone 8 mg tid were given to the patient for 2 weeks. MMF was then switched to Azathioprine 50 mg bid due to gastrointestinal disturbance 2 weeks after MMF was administered. We plan to monitor disease progression as well as aspergilloma progression during immunosuppressive treatment. Serial HRCT follow-up on Figure 2 shows no progression of the aspergilloma as well as the SSc progression.

3. Discussion

SSc is an immunological disease causing increased extracellular matrix deposition, small vessel vasculopathy, T- and B-lymphocyte dysfunction and autoantibody production. This can lead to thickening of the skin and damage to the heart, lung, gastrointestinal tract, and kidneys. Pulmonary involvement can be detected in 70% to 100% of patients.^{3,5} SSc can have a vary clinical manifestations with the majority of the patients having skin thickening and variable internal organ involvement.

The latest classification criteria by the American College of Rheumatology (ACR) and the European League Against Rheumatism (EULAR) are currently the most used criteria to diagnose SSc. Women are predominantly affected with incidence peaking between 45 and 64 years of age.^{1,4} This patient developed symptoms of systemic sclerosis at the age of 40 years.

Pulmonary involvement is the second most often found after skin in progressive SSc. Interstitial thickening of with honeycombed lung is the most common lung parenchymal abnormalities found on chest imaging. Recurrent pulmonary infections are common and they are the most common cause of death in such patients.^{1,2,6}

Aspergilloma is a fungal infection that is often found in patients with immune dysfunction. Aspergilloma or mycetoma is a saprophytic fungal infection that colonizes in the pre-existing lung lesions. However, its association with ILD in systemic sclerosis is a fairly rare case and, therefore, rarely seen in the literature.^{4,7} The spectrum of aspergillus and risk factors for aspergillus-mediated lung disease are

shown in Table 1 and Table 2.^{8,9}

The prevalence of chronic pulmonary aspergillosis varies, with a lower prevalence of less than 1 case per 100000 population in developed countries like the United States. The prevalence can be as high as 42,9 per 100000 in some African nations. Aspergilloma incidence in patients with chronic pulmonary aspergillosis is about 25%.^{7,8} The estimated global 5 years period prevalence is 18/100000. That translates

to a global burden of 1,2 million patients with a higher reported incidence prevalence in Africa, the western Pacific, and Southeast Asia. Isolated aspergilloma without pre-existing parenchymal disease is much rarer, reported at 0,13 %.¹⁰

Table 2 shows that SSc is not mentioned as a risk factor for aspergilloma which indicates that cases of SSc patients with aspergilloma are very rare and have scarcely been found.

Table 1. The spectrum of aspergillus⁸

Disease	Spectrum of aspergillosis
Normal Subject	No disease, possible colonization
Cavitary lung disease	Aspergilloma
Chronic lung disease (ABPA, COPD, lung transplantation, recurrent lower respiratory tract infection, or sarcoidosis with the presence of cough and/or hemoptysis):	Chronic pulmonary aspergillosis
Immunocompromised host or any of the following COPD/ liver cirrhosis/ prolonged steroids treatment/ influenza H1N1/ prolonged ICU admission	Invasive pulmonary aspergillosis
Any of the following asthma/ cystic fibrosis/ blood eosinophil counts > 500 cells/L	Allergic bronchopulmonary aspergillosis

Table 2. Risk factor of aspergillus⁹

1. Pre-existing lung conditions
a. Pulmonary tuberculosis
b. Cystic fibrosis
c. Chronic bronchiectasis
d. Pneumoconiosis
e. Post infarct pulmonary cavity
f. Post radiation pulmonary cavity
g. Sarcoidosis
h. Bronchial cysts and bullae
i. Chronic lung abscess
j. Lung malignancy
k. Ankylosing spondylitis
2. Chronic debilitating condition (impaired local bronchopulmonary defense)
a. Malnutrition
b. COPD
c. Chronic liver disease
3. Immunosuppression
a. Post-transplant
b. Stem cell transplant
c. Chemotherapy
d. Neutropenia
e. Prolonged corticosteroid or immunosuppression use
f. HIV
g. Primary immunodeficiency syndromes

In a relevant clinical setting, characteristic CT chest findings combined with a microbial presence on sputum culture and serological evidence (serum antibodies) clinches the diagnosis. The European Society for Clinical Microbiology and Infectious Diseases, in collaboration with the European Respiratory Society, has published the most comprehensive guideline for diagnosing and determining treatment choices for chronic pulmonary aspergillosis, including aspergilloma.^{5,9} Consistent radiological findings, in association with serological and microbiological evidence of *Aspergillus* species in an individual, with symptoms lasting over three months meet the criteria for diagnosis after excluding another possible differential diagnoses.¹¹

CT helps define the cavity wall thickness, architectural distortion, and inflammation on the parenchyma and pleura, as well as the nature of neovascularization both in lung parenchyma and pleura. Once imaging and microbial are suggestive, the immune response is the next approach in the

algorithm. Assay against galactomannan antigen - a polysaccharide component of the cell wall has high specificity. Usually, the sensitivity of galactomannan antigen is higher in bronchoalveolar lavage fluid than serum, although both tests are available commercially. False-positive are seen in patients concurrently on piperacillin-tazobactam, while false negatives can be seen with high-dose steroid therapy or with other non-*fumigatus* species of *aspergillus*. IgG antibodies against *Aspergillus* species diagnosed by precipitin assay are positive in over 90 % of cases. *Aspergillus*-specific IgE is also fairly elevated.^{7,10,12}

Confirmation of *Aspergillus* species in fungal stain, culture, or polymerase chain reaction, adds weight to the diagnosis but cannot be used as a single diagnostic approach because it has poor diagnostic yield and low sensitivity as well as specificity.¹¹ An isolated sputum culture can be negative in over 50% of cases. Occasionally biopsy and video thoracoscopy can also clinch the diagnosis.^{11,13} Diagnostic criteria for Aspergilloma are shown below.¹³

Table 3. Diagnostic Criteria for Aspergilloma¹³

Term	Definition
Simple Aspergilloma	The single pulmonary cavity containing a fungal ball, with serological or microbiological evidence implicating <i>Aspergillus</i> spp. in a non-immunocompromised patient with minor or no symptoms and no radiological progression over at least 3 months of observation.
CCPA	One or more pulmonary cavities (with either a thin or thick wall) possibly containing one or more aspergillomas or irregular intraluminal material, with serological or microbiological evidence implicating <i>Aspergillus</i> spp. with significant pulmonary and/or systemic symptoms and overt radiological progression (new cavities, increasing pericavitary infiltrates or increasing fibrosis) over at least 3 months of observation.
CFPA	Severe fibrotic destruction of at least two lobes of the lung complicates CCPA leading to major loss of lung function. Severe fibrotic destruction of one lobe with a cavity is simply referred to as CCPA affecting that lobe. Usually, the fibrosis manifests as consolidation, but large cavities with surrounding fibrosis may be seen.
Aspergillus nodule	One or more nodules that may or may not cavitate are an unusual form of CPA. They may mimic tuberculoma, carcinoma of the lung, coccidioidomycosis, and other diagnoses and can only be definitively diagnosed on histology. Tissue invasion is not demonstrated, although necrosis is frequent.
SAIA	Invasive aspergillosis, usually in mildly immunocompromised patients, occurs over 1-3 months, with variable radiological features including cavitation, nodules, and progressive consolidation with "abscess formation". Biopsy shows hyphae in invading lung tissue and microbiological investigations reflect those in invasive aspergillosis, notably positive <i>Aspergillus</i> galactomannan antigen in the blood (or respiratory fluids).

CCPA: chronic cavitary pulmonary aspergillosis; CFPA; chronic fibrosing pulmonary aspergillosis; SAIA: subacute invasive aspergillosis/chronic necrotizing/semi-invasive.

Table 4. Aspergillosis treatment according to several Guidelines¹⁷⁻¹⁹

Diagnosis	American Thoracic Society ¹⁷	Practice Guidelines for the Diagnosis and Management of Aspergillosis ¹⁸	European Respiratory Review ¹⁹
Invasive pulmonary aspergillosis	<ul style="list-style-type: none"> - Primary therapy: voriconazole, liposomal amphotericin B - Salvage therapy: caspofungin, micafungin, posaconazole 	<ul style="list-style-type: none"> - Primary therapy: voriconazole, isavuconazole, liposomal amphotericin B - Alternative therapy: amphotericin B lipid complex, caspofungin, micafungin, posaconazole or itraconazole suspension. 	<ul style="list-style-type: none"> - Primary therapy: voriconazole - Alternative therapy: liposomal amphotericin B, echinocandin or posaconazole
Chronic necrotizing aspergillosis	<ul style="list-style-type: none"> - Mild to moderate disease: voriconazole, itraconazole - Severe disease: liposomal amphotericin B, IV voriconazole 	<ul style="list-style-type: none"> - Without symptoms: observed - With symptoms: itraconazole, voriconazole, posaconazole 	<ul style="list-style-type: none"> - Primary therapy: voriconazole - Alternative therapy: itraconazole, IV voriconazole or liposomal amphotericin B (in severe disease)
Aspergilloma	<ul style="list-style-type: none"> - No indication for antifungal agents. - Bronchial angiography and embolization, surgical resection 	<ul style="list-style-type: none"> - Stable: observed - Hemoptysis: surgically resect 	<ul style="list-style-type: none"> - Without symptoms: observed - With symptoms: Bronchial - angiography and embolization, surgical resection, consider itraconazole
Allergic bronchopulmonary aspergillosis	<ul style="list-style-type: none"> - Primary therapy: corticosteroids - Other therapy: itraconazole, voriconazole as steroid sparing agents 	Corticosteroids, Oral itraconazole as steroid sparing agent	<ul style="list-style-type: none"> - Primary therapy: corticosteroids - Other therapy: itraconazole, voriconazole as steroid sparing agents

Table 5. Case report of CLL patient with aspergillus²⁰

No	Subject	Diagnosis	Therapy	Result	Advanced Therapy	Final Result
1	Female, 60 yo ²⁰	CLL + Fusarium with Aspergillus	<ul style="list-style-type: none"> - Alemtazumab (Campath - 1H) for CLL - Voriconazole 	<ul style="list-style-type: none"> - Clinical improvement, CD4 cell count remains low - 3 months later, chronic pneumonia was found 	Right lung resection	Patient experienced mucormycosis or mucormycosis superinfection as a side effect of voriconazole administration

This patient has SSc and ILD as the underlying disease to a developed aspergilloma. In addition, the immunosuppressive agent that she received (MMF then switched to azathioprine) can exacerbate further immunodeficiency deterioration.

The patient was diagnosed with aspergilloma from the clinical symptoms and HRCT scan thorax that shows subpleural honeycombing appearance predominantly on the basal of the lung and air crescent sign with traction bronchiectasis that substantiates interstitial lung disease UIP pattern with fungus ball aspergilloma, nodular thickening of bilateral pleura, which are in accordance with the

guidelines that delineate the diagnosis of aspergilloma. Pathophysiology of aspergillosis begins with the entry of *conidia Aspergillus* spp. into the lungs. Then, conidia become hyphae and accumulate in the lungs, triggering an inflammatory response by aggregating neutrophils and macrophages to produce inflammatory cytokine.¹⁵ In this case, the patient suffers from systemic sclerosis and had an immunosuppressive drug which can worsen the aspergilloma. An immunosuppressive agent can suppress the immune system that decreases the body's ability to eliminate *Aspergillus* spp. that penetrates the human lung. Systemic sclerosis is a systemic inflammation that can cause epithelial cell

injury and activation of the coagulation pathway, which creates a profibrogenic environment in the lung in the setting of autoimmunity.¹⁶ Fortunately, despite the immunosuppressive agent that she received for 4 months, our patient's clinical condition is improved with no sign of the worsening condition of the fungal ball aspergilloma from the HRCT evaluation.

In our patient, surgical resection was not considered due to patient preferences. Antifungals can be used as the mainstay of treatment in our patients where surgery is not available or feasible. Although the drug does not penetrate the cavity of the aspergilloma well, some researchers have found itraconazole to be 60-70% effective in stabilizing or improving symptoms and reducing progression. Currently, itraconazole is most widely used but voriconazole and intravesicular amphotericin B can be used for secondary treatment. It is not clear whether antifungal therapy as an adjuvant to surgery has a significant impact on postoperative morbidity or long-term survival. Radiologic improvement and resolution rarely occur in symptomatic cases.¹⁵⁻²⁰

4. Conclusion

Systemic sclerosis (SSc) is a rare autoimmune disease involving the skin and internal organs. The immunosuppressive agent is still the drug of choice for most autoimmune diseases. Immunosuppressive may promote fungal growth and have been associated with increased risk in most serious fungal diseases including aspergilloma.

5. References

1. LeRoy EC, Black C, Fleischmajer R, Jablonska S, Krieg T, et al. Scleroderma (systemic sclerosis): classification, subsets and pathogenesis. *J Rheumatol*, 1988; 15(2):202-205.
2. Nihtyanova SI, Schreiber BE, Ong VH, Rosenberg D, Moinzadeh P, et al. Prediction of pulmonary complications and long-term survival in systemic sclerosis. *Arthritis Rheumatol*, 2014; 66(6):1625-1635.
3. Denning DW, Cadranel J, Beigelman-Aubry C, Ader F, Chakrabarti A, et al. European society for clinical microbiology and infectious diseases and European respiratory society. Chronic pulmonary aspergillosis: rationale and clinical guidelines for diagnosis and management. *Eur Respir J*, 2016; 47(1):45-68.
4. Diot P, Diot E, Lemarie E, Guilmot JL, Baulieu JL, et al. Imaging of pulmonary disease in scleroderma with J001X scintigraphy. *Thorax*, 1994; 49(5):504-508.
5. van den Hoogen F, Khanna D, Fransen J, Johnson SR, Baron M, et al. 2013 classification criteria for systemic sclerosis: an American college of rheumatology/European league against rheumatism collaborative initiative. *Ann Rheum Dis*, 2013; 72(11):1747-1755.
6. Al-Jahdali H, Rajiah P, Allen C, Koteyar SS, Khan AN. Pictorial review of intrathoracic manifestations of progressive systemic sclerosis. *Ann Thorac Med*, 2014; 9(4):193-202.
7. Rakotoson JL, Vololontiana HM, Raherison RE, Andrianasolo R, Rakotomizao JR, et al. A rare case of huge aspergilloma developed within a lesion of pulmonary fibrosis secondary with a systemic scleroderma in an immunocompetent patient in Madagascar. *Bull Soc Pathol Exot*, 2011; 104(5):325-328.
8. Pappas PG, Kauffman CA, Andes DR, Clancy CJ, Marr KA, et al. Clinical practice guideline for the management of candidiasis: 2016 Update by the Infectious Diseases Society of America. *Clin Infect Dis*, 2016; 62(4):1-50.
9. Baxter CG, Dunn G, Jones AM, Webb K, Gore R, et al. Novel immunologic classification of aspergillosis in adult cystic

- fibrosis. *J Allergy Clin Immunol*, 2013; 132(3):560-566.
10. Soubani AO, Chandrasekar PH. The clinical spectrum of pulmonary aspergillosis. *Chest*, 2002; 121(6):1988-1999.
 11. Zmeili OS, Soubani AO. Pulmonary aspergillosis: a clinical update. *QJM*, 2007; 100(6):317-334.
 12. Del Bono V, Mikulska M, Viscoli C. Invasive aspergillosis: diagnosis, prophylaxis and treatment. *Curr Opin Hematol*, 2008; 15(6):586-593.
 13. Walsh TJ, Anaissie EJ, Denning DW, Herbrecht R, Kontoyiannis DP, et al. Infectious diseases society of America. Treatment of aspergillosis: clinical practice guidelines of the Infectious Diseases Society of America. *Clin Infect Dis*, 2008; 46(3):327-360.
 14. Gonçalves SS, Souza ACR, Chowdhary A, Meis JF, Colombo AL. Epidemiology and molecular mechanisms of antifungal resistance in *Candida* and *Aspergillus*. *Mycoses*, 2016; 59(4):198-219.
 15. Patterson TF, Thompson GR, Denning DW, Fishman JA, Hadley S, et al. Practice Guidelines for the Diagnosis and Management of Aspergillosis: 2016 Update by the Infectious Diseases Society of America. *Clin Infect Dis*, 2016;63(4): 1-60.
 16. Walsh TJ, Anaissie EJ, Denning DW, Herbrecht R, Kontoyiannis DP, et al. Infectious diseases society of America. Treatment of aspergillosis: clinical practice guidelines of the Infectious Diseases Society of America. *Clin Infect Dis*, 2008; 46(3):327-360.
 17. Segal BH, Walsh TJ. Current approaches to diagnosis and treatment of invasive aspergillosis. *Am J Respir Crit Care Med*, 2006; 173(7):707-717.
 18. O'Brien AA, Moore DP, Keogh JA. Pulmonary berylliosis on corticosteroid therapy, with cavitating lung lesions and aspergillomata--report on a fatal case. *Postgrad Med J*, 1987; 63(7):797-799.
 19. Perfect JR. The impact of the host on fungal infections. *Am J Med*, 2012; 125(1):39-51.
 20. Abreu I, Guedes M, Duro R, Lopes S, Maciel J, et al. Pleural aspergillosis in a patient with recurrent spontaneous pneumothorax: The challenge of an optimal therapeutic approach. *Med Mycol Case Rep*, 2020; 28(2):4-7.